



Mpox Update: Stay Up to Date on Testing, Treatment, and Vaccination

Clinician Outreach and Communication Activity (COCA) Call

Thursday, May 18, 2023

Continuing Education

- Continuing education is not offered for this webinar.

To Ask a Question

- Using the Zoom Webinar System
 - Click on the “Q&A” button
 - Type your question in the “Q&A” box
 - Submit your question
- If you are a patient, please refer your question to your healthcare provider.
- If you are a member of the media, please direct your questions to CDC Media Relations at 404-639-3286 or email media@cdc.gov.

Today's Presenters

John T. Brooks, MD

Chief Medical Officer

Division of HIV Prevention

National Center for HIV, Viral Hepatitis, STD, and TB Prevention

Centers for Disease Control and Prevention

Chris Braden, MD

Incident Manager

2022 Multinational Mpox Response

National Center for Emerging and Zoonotic Infectious Diseases

Centers for Disease Control and Prevention

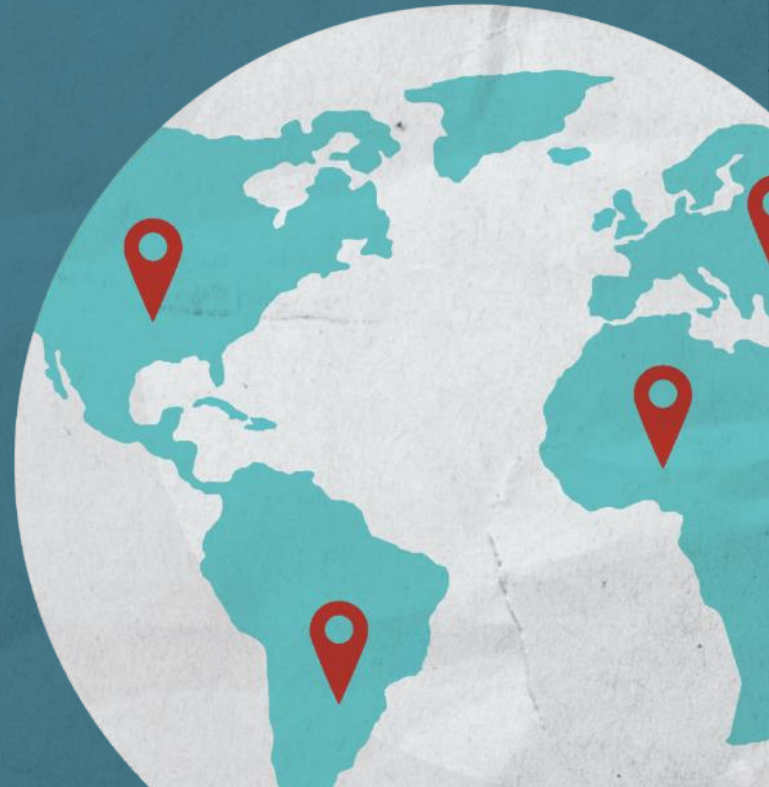MPOX

Mpox Update: Stay Up to Date on Testing, Treatment, and Vaccination

Clinician Outreach and
Communication Activity Call
(COCA)

John T. Brooks, MD and Chris Braden, MD

May 18, 2023



Key Learning Objectives Today

In light of limited clusters of new mpox cases

1. Renew clinical awareness for early recognition of potential cases of mpox
2. Review basic clinical presentation and management of mpox
3. Highlight that tecovirimat should first be requested through STOMP study
4. Promote vaccination of people at risk for mpox
5. Share update about recent infections reported from Chicago

Up-to-Date CDC Situation Summary

<https://www.cdc.gov/poxvirus/mpox/response/2022/index.html>

2022 Outbreak Cases and Data

Data as of May 17 2023 at 2:00 pm EDT

[Español](#) [Print](#)

Beginning February 1, 2023, the data below will be updated every two weeks.

U.S. Cases

Total Cases

30,401

U.S. Deaths

Total Deaths

42

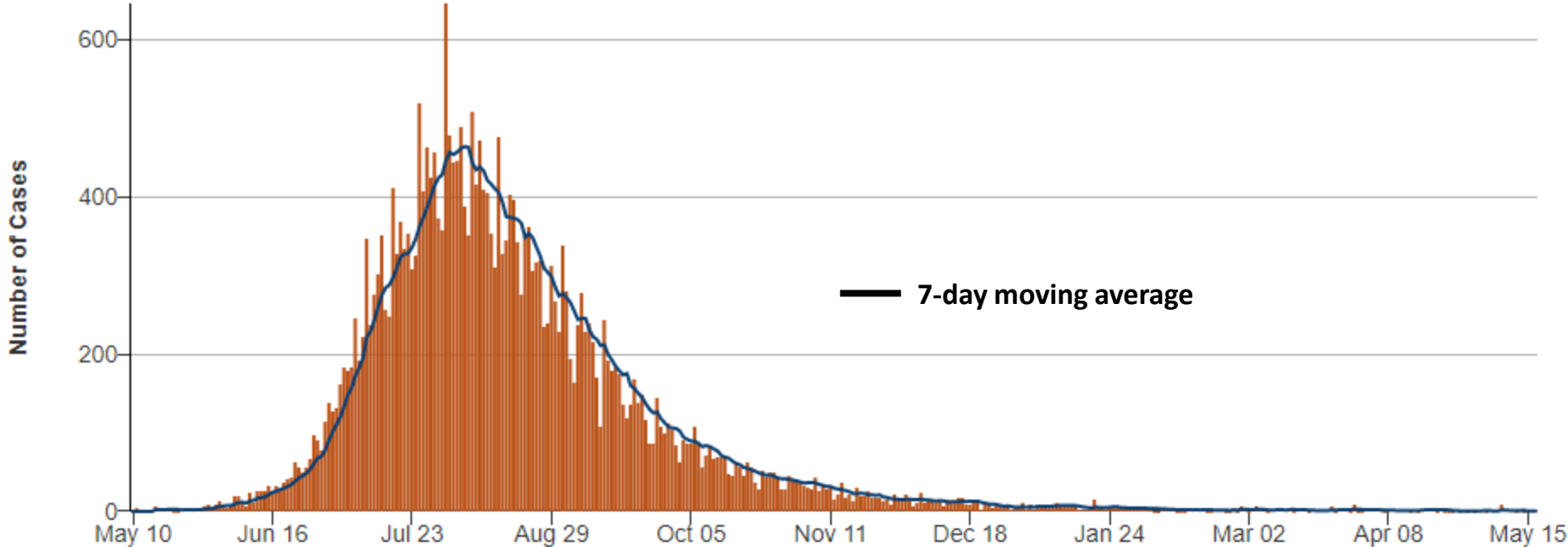
Global Cases

Total Cases

87,314

Maps, case counts, demographics, vaccine administration and effectiveness, technical reports

Mpox Cases: U.S. Trends



Case from May 11, 2022 through May 17, 2023

Source: [U.S. Monkeypox Case Trends Reported to CDC](#) | [Monkeypox](#) | [Poxvirus](#) | [CDC](#)

Mpox Virus: Divided into Two Main Clades

Clade I

- Formerly Congo basin clade
- More virulent (CFR ~10%)

Clade II

- Formerly West African clade
- Less virulent (CFR <1%)
- 2022 outbreak strain is sub-clade IIb

Journal of General Virology (2005), 86, 2661–2672 DOI: 10.1099/vir.081215-0



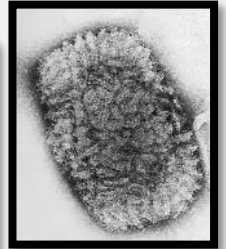
A tale of two clades: monkeypox viruses

Anna M. Likos,¹† Scott A. Sammons,¹† Victoria A. Olson,¹
A. Michael Frace,¹ Yu Li,¹ Melissa Olsen-Rasmussen,¹ Whitney Davidson,¹
Renee Galloway,¹ Marina L. Khristova,¹ Mary G. Reynolds,¹ Hui Zhao,¹
Darin S. Carroll,¹ Aaron Curns,¹ Pierre Formenty,² Joseph J. Esposito,¹
Russell L. Regnery¹ and Inger K. Damon¹

¹National Center for Infectious Disease, Centers for Disease Control and Prevention, 1600 Clifton Road

²World Health Organization

Correspondence:
Inger K. Damon
iak7@cdc.gov



Available online at www.sciencedirect.com

SCIENCE @ DIRECT®

Virology 340 (2005) 46–63

VIROLOGY

www.elsevier.com/locate/yviro

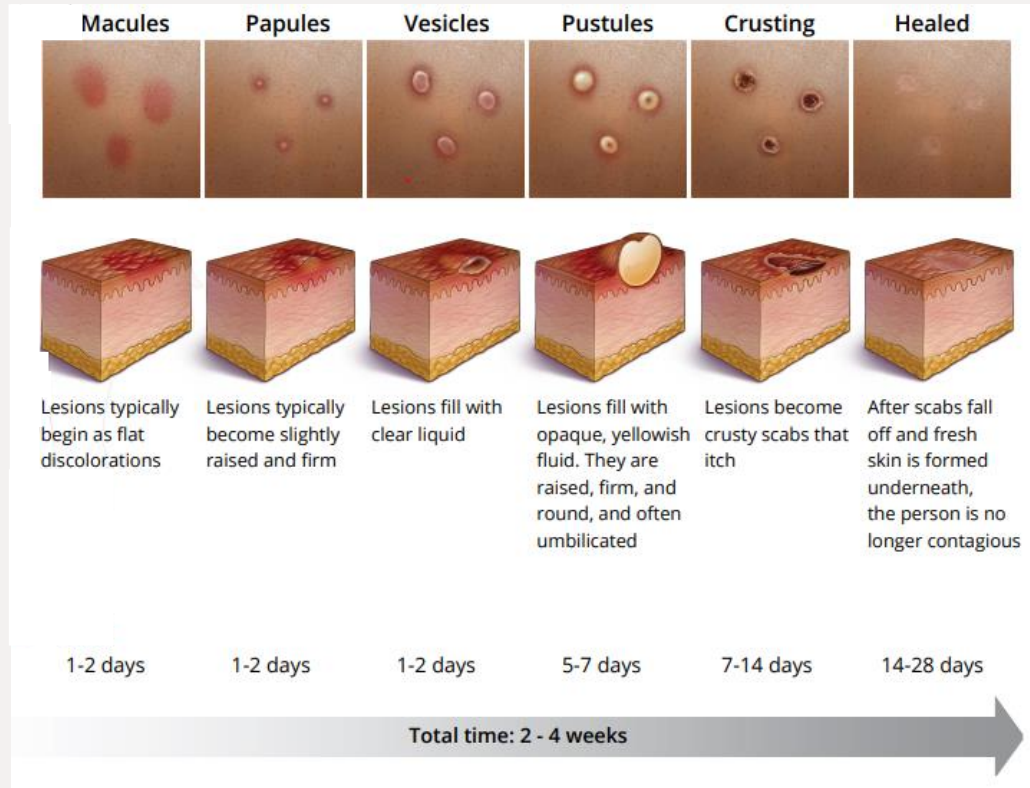
Virulence differences between monkeypox virus isolates from West Africa and the Congo basin

Nanhai Chen^{a,1}, Guiyun Li^{b,1}, M. Kathryn Liszewski^c, John P. Atkinson^c, Peter B. Jahrling^d,
Zehua Feng^e, Jill Schriewer^e, Charles Buck^c, Chunlin Wang^f, Elliot J. Lefkowitz^f,
Joseph J. Esposito^g, Tiara Harms^g, Inger K. Damon^g, Rachel L. Roper^h,
Chris Upton^g, R. Mark L. Buller^{a,*}

Mpox: Course of Illness

- Incubation period: 3–17 days¹
- Illness duration: 2–4 weeks²
- Development of initial symptoms marks beginning of prodromal period
 - Fever, malaise, headache, weakness, myalgia
- Febrile prodrome lasts 1–4 days
- Lymphadenopathy: generalized or localized to several areas
- Rash lesions:
 - Progress predictably through stages: macule, papule, vesicle, pustule, crust
 - Pustules typically well circumscribed, deep seated, and often umbilicated
 - Are frequently painful, then become pruritic during the healing phase

Mpox: Progression of Lesions



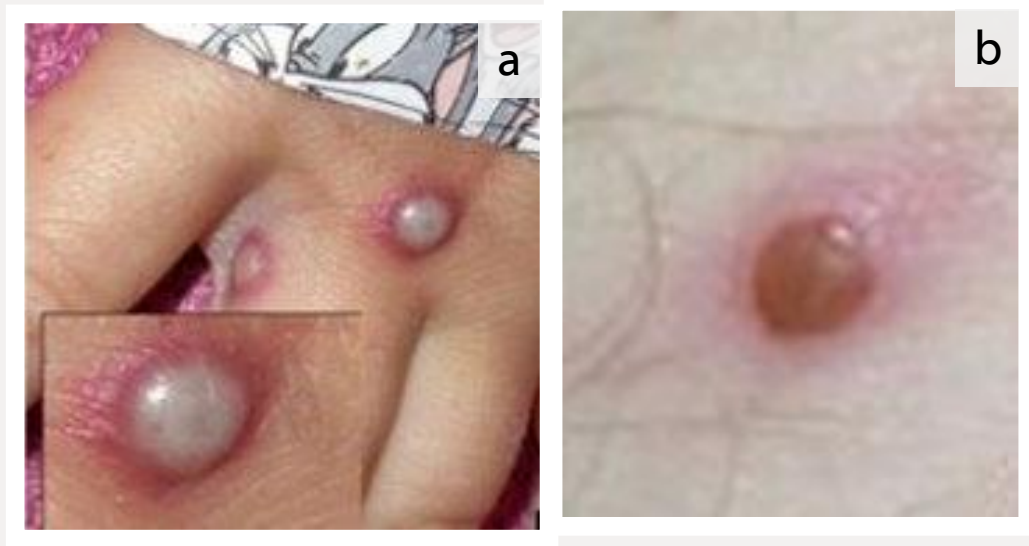
Clade IIb Mpox Outbreak: Clinical Characteristics

- Disproportionately affecting young MSM*, including MSM with HIV
- Transmission predominately linked to sexual contact
- Rash:
 - Lower burden of lesions
 - Distribution more centrifugal (abdomen/pelvis) than centripetal (arms/legs/face)
 - Affects both skin ***and mucosa***, especially anus, genitalia and oropharynx
- Fewer “prodromal” symptoms; they could be absent or follow rash onset
- Immunocompromised experience more severe and more prolonged illness, especially persons with HIV and low CD4 cell counts or unsuppressed viral loads

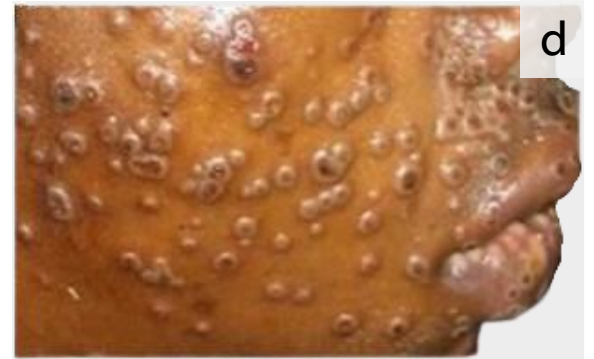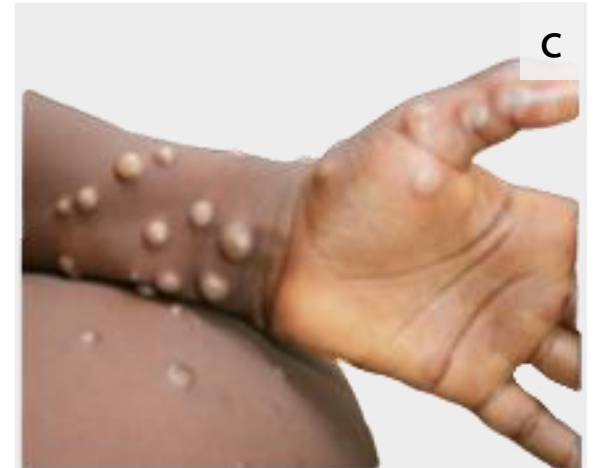*MSM = gay, bisexual, same gender-loving, and other men who have sex with men

Classic Rash Presentation

Note centripetal distribution (arms/legs/face)



Lesions seen in the 2003 U.S. mpox outbreak



Lesions seen in endemic countries

Clade IIb Rash Presentation

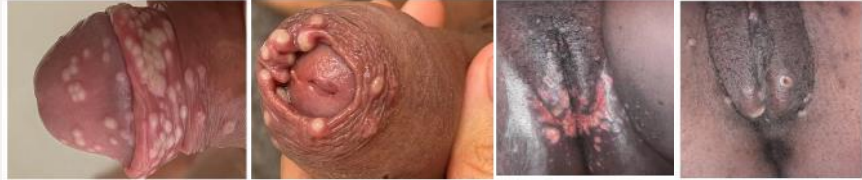Site of skin lesions	Number (%)*
Anogenital area	383 (73)
Face	134 (25)
Trunk or limbs	292 (55)
Palms or soles	51 (10)

*More than one site per person may have been reported.

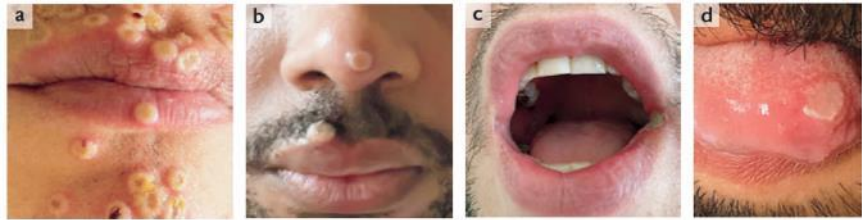
Mucosal lesions present—no. (%)	217 (41)
---------------------------------	----------

Site of mucosal lesions	Number/Total Number (%)
Anogenital only	148/217 (68)
Oropharyngeal only	50/217 (23)
Anogenital and oral	16/217 (7)
Nasal and eye	3/217 (1)

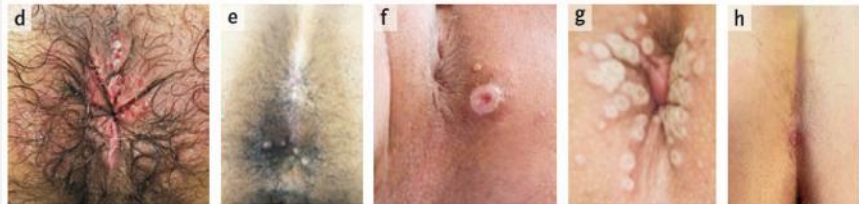
Penile and Vulvovaginal Lesions



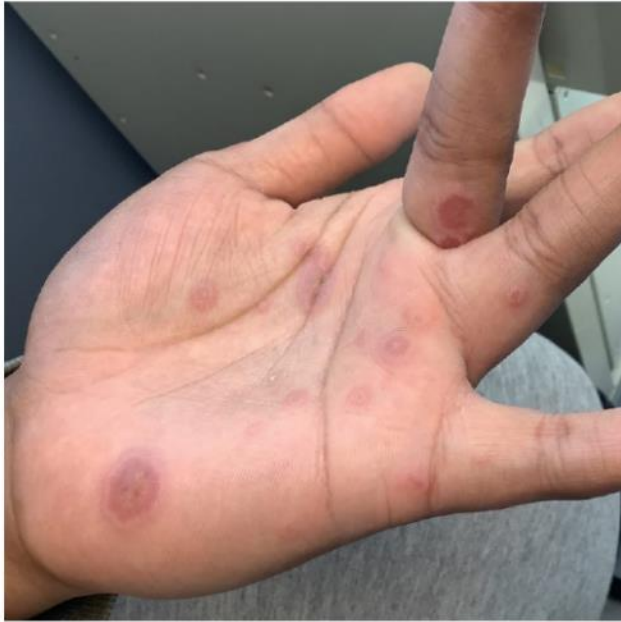Oral Lesions



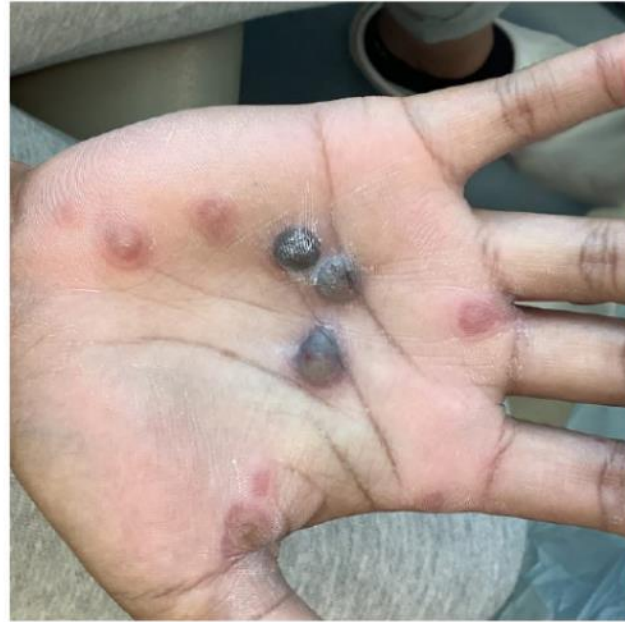Anorectal Lesions



Clade IIb Rash Presentation



Macules on hand and finger



Multiple stages of evolutions of macules on palm

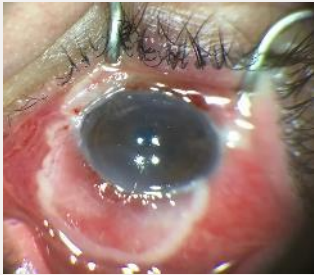Patients at Risk for Severe Mpox

- People with
 - Underlying medical conditions
 - Inadequately treated HIV (CD4+ counts < 350 cells/mm³)
 - Immunosuppression (e.g., organ transplant, therapy for autoimmune disorder, chemotherapy)
 - Moderate or severe primary immunodeficiency
 - History of atopic dermatitis, eczema, or extensive breaks in the dermal barrier

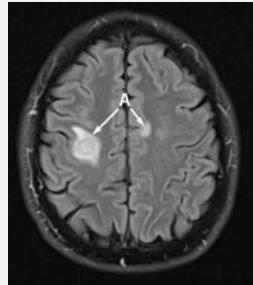
Mpox: Severe Complications

- Ophthalmologic: conjunctivitis, corneal ulceration and scarring
- Neurologic: confusion, seizure, encephalomyelitis
- Cardiovascular: myocarditis, pericarditis
- Rheumatologic: acute arthritis/synovitis

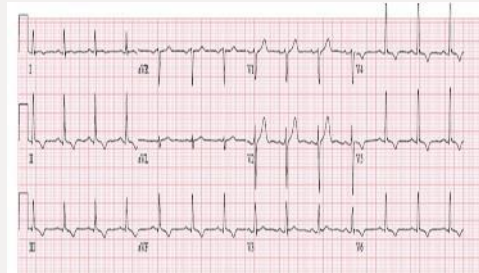
Conjunctival lesion with corneal ulceration



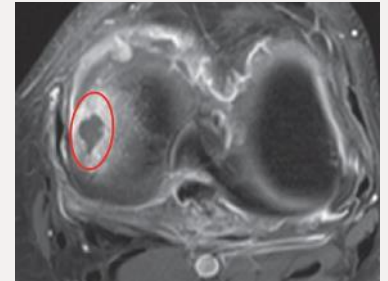
Abnormal T2/fluid attenuated inversion recovery signal



Inferior and anterolateral T-wave inversions



Synovitis with subchondral demarcation zone (red circle)



Mpox: Severe Complications Continued...

- Obstructions (most often in the lungs or gastrointestinal tract) secondary to
 - Ulcer-related strictures
 - Severe lymphadenopathy
 - Edema of surrounding tissue
- Sepsis/hemorrhagic disease
- Death

Transmission

Mpox: Transmission

- Spread person-to-person through direct contact
 - Physical contact with infectious skin rash or scabs
 - Anogenital/oropharyngeal mucosal contact
 - Touching heavily soiled items (e.g., clothing, linens)
 - Placental transfer to fetus
- Patients can be infectious up to 4 days before symptoms begin, (whether prodromal or rash symptoms) and remain infectious until lesions form scabs, scabs fall off, and a fresh layer of skin forms



Sources: CDC [2022], [Science Brief: Detection and Transmission of Mpox](#), webpage.

CDC [2022], [Isolation and Prevention Practices for People with Mpox](#), webpage. Beeson 2023, [Lancet Microbe](#).

Mpox: Transmission Continued...

- Risk of infection through contact with low-level contaminated surfaces or objects in household or healthcare setting is considered low
- Transmission during brief interactions or between people in close proximity and for a long duration (such as passengers seated near a person with mpox on an airplane) is unlikely
- How often mpox virus is spread via respiratory secretions is unknown

Sources: CDC [2022], [Science Brief: Detection and Transmission of Mpox](#), webpage.

CDC [2022], [Isolation and Prevention Practices for People with Mpox](#), webpage. Beeson 2023, *Lancet Microbe*.

Physical Examination, Specimen Collection, and Testing

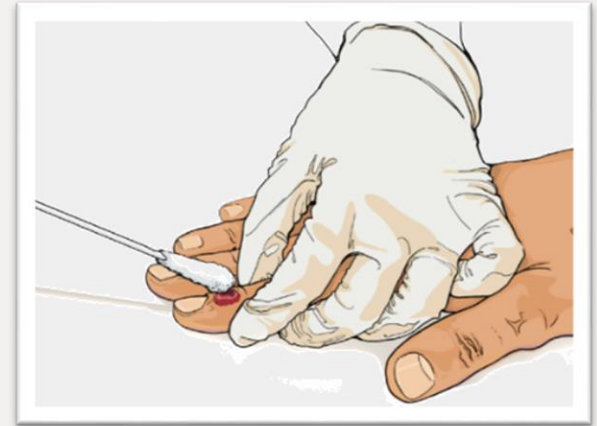
Mpox: Examination and Diagnosis

Frontline clinicians may first encounter patients with mpox

- Collect a complete sexual, social, and travel history for past 21 days
- Perform a thorough skin and mucosal examination (e.g., genital, anal, oral) in a room with *good lighting*
- Consider a broad differential such as syphilis, varicella zoster, herpes simplex, molluscum contagiosum, pharyngeal group A streptococcus
- Evaluate for STIs per the [2021 CDC STI Treatment Guidelines](#)
 - Persons with monkeypox may have other STIs including acute HIV
- Notify the health department of suspected, probable, and confirmed cases

Mpox: Specimen Collection

- Wear recommended personal protective equipment (PPE)
 - **Do not unroof or aspirate lesions** (or use sharp instruments for mpox testing) due to the risk for sharps injury
 - In severe cases, the CDC Infection Diseases Pathology Branch can assist when a biopsy is performed



Sources: CDC [2022], [Infection Prevention and Control of Mpox in Healthcare Settings](#), webpage.
CDC [2022], [Tips for Adequate Collection of a Lesion Specimen from a Suspect Monkeypox](#), webpage,
CDC [2022], [Guidelines for Collecting and Handling Specimens for Mpox Testing](#), webpage.
CDC [2022], [Additional Testing of Biopsy Tissues in Severe Mpox Infections](#), webpage.

Mpox: Testing

- Skin lesion material is the recommended specimen for initial [laboratory testing](#) at either
 - Commercial laboratories
 - At a facility within the [Laboratory Response Network](#)
- Contact the appropriate [public health department](#) or commercial laboratory to determine criteria for acceptable specimens, as this may vary
- There is a specific protocol for [submitting specimens to the CDC](#), which may differ from that of local health departments
- **High clinical suspicion is sufficient to initiate treatment**

Other Infections Causing Rash or Proctitis

- Syphilis
- Herpes zoster
- Disseminated varicella zoster
- Disseminated herpes
- Molluscum contagiosum
- Lymphogranuloma venereum (LGV)
- Disseminated fungal infections
- Disseminated gonococcal infection
- Scabies
- Hand, foot, and mouth disease
- Chancroid
- Granuloma inguinale

Clinicians should be aware that patients may have concurrent infections.

Diagnostic Evaluation for both Genital Ulcers and Proctitis

- Initial evaluation
- Syphilis serologic tests
 - If available, darkfield examination or nucleic acid amplification test (NAAT) from lesion exudate or tissue
- NAAT for gonorrhea and chlamydia
- NAAT* or culture for genital herpes type 1 and 2

Clinicians should be aware that patients may have concurrent infections.

*Preferred

Treatment

Mpox: Clinical Management


- Mpox infection is often mild and self-limiting without specific antiviral therapy
- Pain management, skin care, and wound care are often vital components of mpox treatment plans

Sources: CDC [2022], [Treatment Information for Healthcare Professionals](#), webpage.
CDC [2022], [Clinical Considerations for Pain Management of Mpox](#), webpage.
American Academy of Dermatology [2022], [Mpox Caring for the Skin](#), webpage.

Tecovirimat (aka TPOXX): Background

- Antiviral approved by the FDA for treatment of human smallpox (not mpox)
 - May be used for non-variola orthopoxvirus infection (e.g., mpox) under a CDC-held [Expanded Access Investigational New Drug Protocol](#) for adults and children weighing at least 3 kg
- Mpox treatment efficacy
 - Animal studies suggest mortality benefit
 - Human case reports report anecdotal evidence of reduced severity and duration of illness and viral shedding
 - HOWEVER human efficacy remains unknown
- Mpox postexposure prophylaxis (PEP) efficacy is unstudied

Tecovirimat: Availability

- Available through
 - [Study of Tecovirimat for Human Mpox Virus](#) ( **STOMP**)
 - Some health departments (limited supplies)
- Oral capsules
 - Must be taken with a full, fatty meal for adequate absorption
 - May be opened and mixed with soft food for pediatric patients <13kg
- Oral and intravenous (IV) formulations available through the Strategic National Stockpile (SNS) via consultation/email with state/local health authorities or CDC as needed

Mpox: Clinical Management

- **Patients with underlying immunocompromise (esp. advanced HIV) are at risk for severe, systemic, protracted illness and death and likely need combination therapy**
- CDC is available for clinical consultation, as needed
- CDC Emergency Operations Center
 - **Phone:** 770-488-7100
 - **Email:** poxvirus@cdc.gov
- Prompt consultation with CDC is recommended for immunocompromised patients and patients at risk for severe mpox

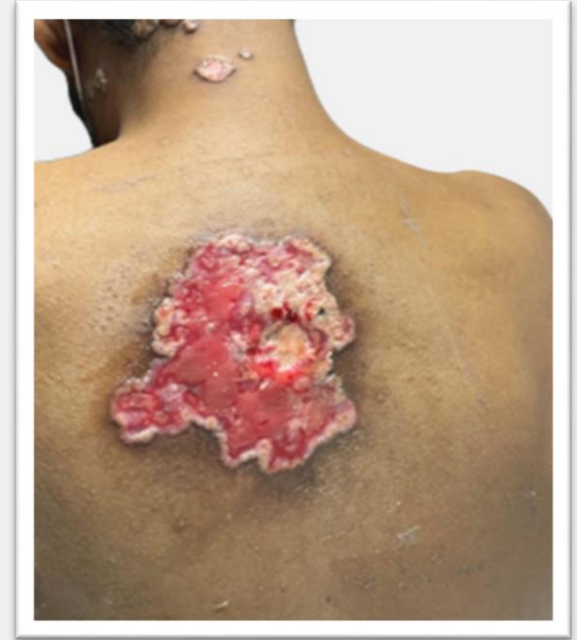

Photo Credits: Photo appears in Miller MJ et al.

Optimize Immune Function

- For immunocompromised patients
 - Optimize native immunity (e.g., ensure persons with HIV are receiving effective antiretroviral therapy)
 - Limit the use of immunocompromising therapies (e.g., chemotherapy, corticosteroids)

Mpox Vaccination

JYNNEOS Vaccine

- Live virus vaccine produced from the *replication-deficient* vaccinia virus strain
 - Modified Vaccinia Ankara-Bavarian Nordic (MVA-BN)
 - Also known as IMVAMUNE, IMVANEX, MVA
- FDA licensed in 2019 to prevent smallpox and mpox in adults ≥ 18 years old¹
- May be administered intradermally or subcutaneously for persons ≥ 18
 - Subcutaneously for persons < 18 under Emergency Use Authorization
- Administration in 2 doses at least 4 weeks apart
- Can be used either:
 - Before potential exposure (pre-exposure prophylaxis)
 - After exposure (post-exposure prophylaxis)

Sources: FDA [2022], [Jynneos](#), webpage.

CDC [2022], [JYNNEOS Smallpox and Monkeypox Vaccine Intradermal Administration](#), webpage with pdf.

CDC [2022], [JYNNEOS Smallpox and Monkeypox Vaccine Subcutaneous Administration](#), webpage with pdf.

JYNNEOS Vaccine: Safety

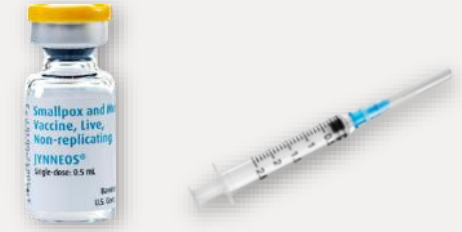- **Safe for use in those who are immunocompromised** or have atopic dermatitis
- Demonstrated to be safe in current outbreak
- Safety not established in:
 - Pregnant persons, breastfeeding persons, or children
- Animal models using high doses showed no harm to a developing fetus
- Contraindicated in patients with prior severe allergic reaction to JYNNEOS
- **Use with caution in those with allergy to eggs, gentamicin, or ciprofloxacin**
 - Produced using chicken embryo fibroblast cells
 - Contains small amounts of gentamicin and ciprofloxacin

Sources: FDA [2022], [Jynneos](#), webpage.

CDC [2022], [JYNNEOS Smallpox and Monkeypox Vaccine Intradermal Administration](#), webpage with pdf.

CDC [2022], [JYNNEOS Smallpox and Monkeypox Vaccine Subcutaneous Administration](#), webpage with pdf.

JYNNEOS Vaccine: Efficacy



Vaccine performance

- Vaccine effectiveness (VE) ranged
- No differences observed between intradermal or subcutaneous routes

Study population	Cases; Controls	Vaccination status	VE for 2 doses (95% CI)	VE for 1 dose (95% CI)
Epic national dataset case-control study	2,193 cases; 8,319 controls	Full: 3%, Partial: 11%, Unvaccinated: 86%	66% (47-88%)	36% (22-47%)
Multi-jurisdictional case-control study	309 cases; 608 controls	Full: 23% Partial: 32% Unvaccinated: 45%	86% (74-92%)	75% (61-84%)
New York state case-control study	252 cases; 255 controls	Full: 0.8% Partial: 8% Unvaccinated: 91%	89% (44-98%)	68% (25-87%)

Vaccination Prior to Exposure

Mpox Vaccination Indications: Sexual History Risk Factors (1/2)

Offer mpox vaccination to adults/adolescents, who over the last 6 months:

Were diagnosed with a sexually transmitted infection

OR

Had a new sex partner

AND

Are gay, bisexual, or are other men who have sex with men

OR

Are transgender or nonbinary

Mpox Vaccination Indications: Sexual History Risk Factors (2/2)

- Offer mpox vaccination to anyone
 - Who has had sex during the last 6 months
 - At a commercial sex venue or other social gathering
 - In association with a large public event in an area with ongoing mpox transmission
 - With a partner with the above risks
 - Who has HIV infection or other causes of immunosuppression who have had recent or anticipate possible future risk of mpox exposure

Vaccination After to Exposure

Mpox Vaccine Postexposure Prophylaxis

- Risk exposure assessment determines need for vaccination of close contacts
- Initiate post-exposure prophylaxis (PEP)*
 - Within 4 days of suspected exposure to minimize disease incidence
 - From 4–14 days after suspected exposure to reduce illness severity

*Based on data from live, replicating vaccinia virus vaccines for smallpox

Sources: CDC [2022]. [Interim Clinical Considerations for Use of JYNNEOS and ACAM2000 Vaccines](#), webpage.
CDC [2022], [Monitoring and Risk Assessment for Persons Exposed in the Community](#), webpage with pdf.




For clinical consultation, please contact

CDC Emergency Operations Center Phone: (770) 488-7100

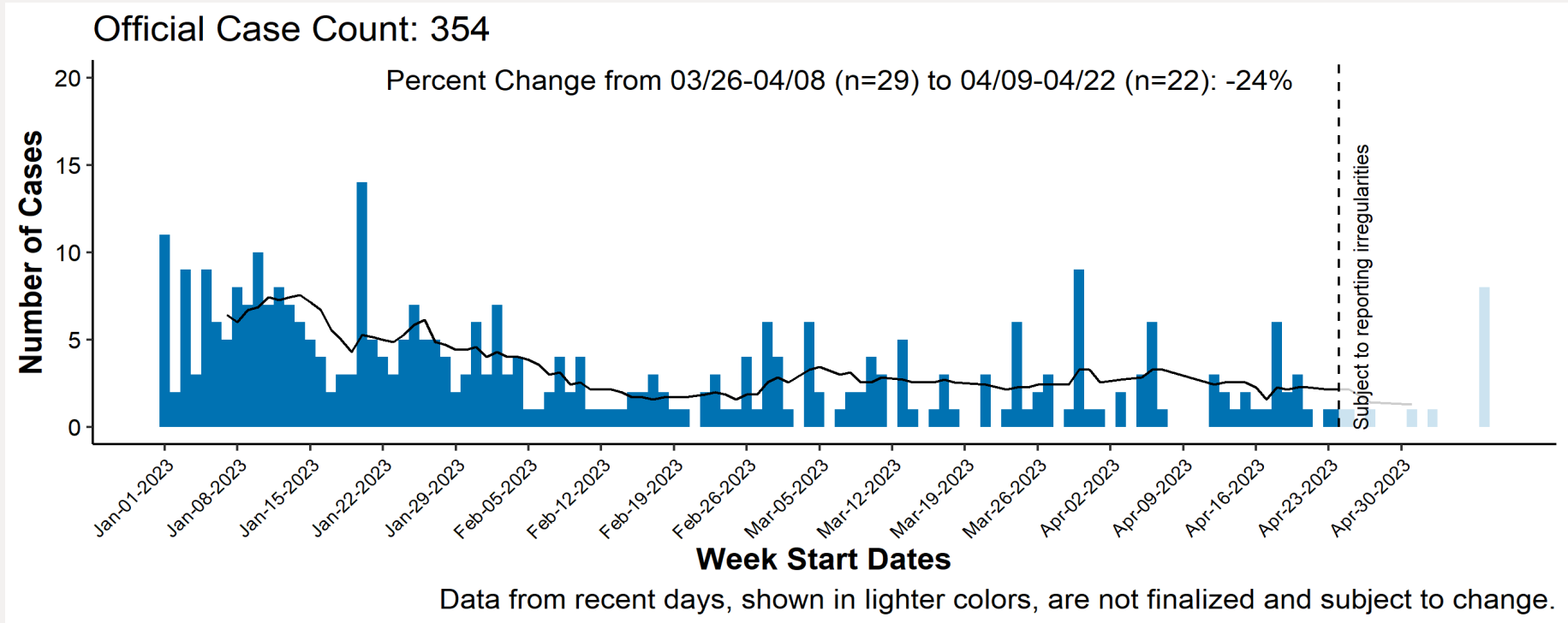
Email: poxvirus@cdc.gov

The findings and conclusions in this report are those of the authors and do not necessarily represent the official position of the Centers for Disease Control and Prevention.

CDC's Ongoing Mpox Response Update



Mpox cases reported to CDC: Epi Curve (since 2023) with 7-day moving average (As of 05/10/2023 at 2pm ET)



Mpox cases in IL

Situation as of 5/15/2023

- March 18 through May 15, 2023— 21 cases reported to the Chicago Dep. of Public Health
 - All male
- 17 cases (of 21 with information) were vaccinated
 - 11 with 2 dose JYNNEOS, 1 with ACAM2000, 5 with 1 dose JYNNEOS
- 5 had well controlled HIV
- None were hospitalized
- 6 (of 18 with information) had recently traveled (U.S. destinations and Mexico)

Joining the Q&A Session

Rosalind J. Carter, PhD

Clinical Liaison

2022 Multinational Mpox Response

Centers for Disease Control and Prevention

Agam Rao, MD, FIDSA

CAPT, U.S. Public Health Service

Lead, Advisory Committee on Immunization Practices

Centers for Disease Control and Prevention

Andrea McCollum, PhD

Epidemiology Team Lead

2022 Multinational Mpox Response

Centers for Disease Control and Prevention

Brett Petersen, MD, MPH

Deputy Chief

National Center for Emerging and Zoonotic Infectious
Diseases

Centers for Disease Control and Prevention

To Ask a Question

- Using the Zoom Webinar System
 - Click on the “Q&A” button
 - Type your question in the “Q&A” box
 - Submit your question
- If you are a patient, please refer your question to your healthcare provider.
- If you are a member of the media, please direct your questions to CDC Media Relations at 404-639-3286 or email media@cdc.gov.

Today's COCA Call Will Be Available to View On-Demand

- **When:** A few hours after the live call ends*
- **What:** Video recording
- **Where:** On the COCA Call webpage
https://emergency.cdc.gov/coca/calls/2023/callinfo_051823.asp

**A transcript and closed-captioned video will be available shortly after the original video recording posts at the above link.*

Additional Resources

- Continue to visit emergency.cdc.gov/coca for more details about upcoming COCA Calls.
- Subscribe to receive notifications about upcoming COCA calls and other COCA products and services at emergency.cdc.gov/coca/subscribe.asp.

Thank you for joining us today!



emergency.cdc.gov/coca